The Root of the Neck

The root of the neck can be defined as the area of the neck immediately above the inlet into the thorax.

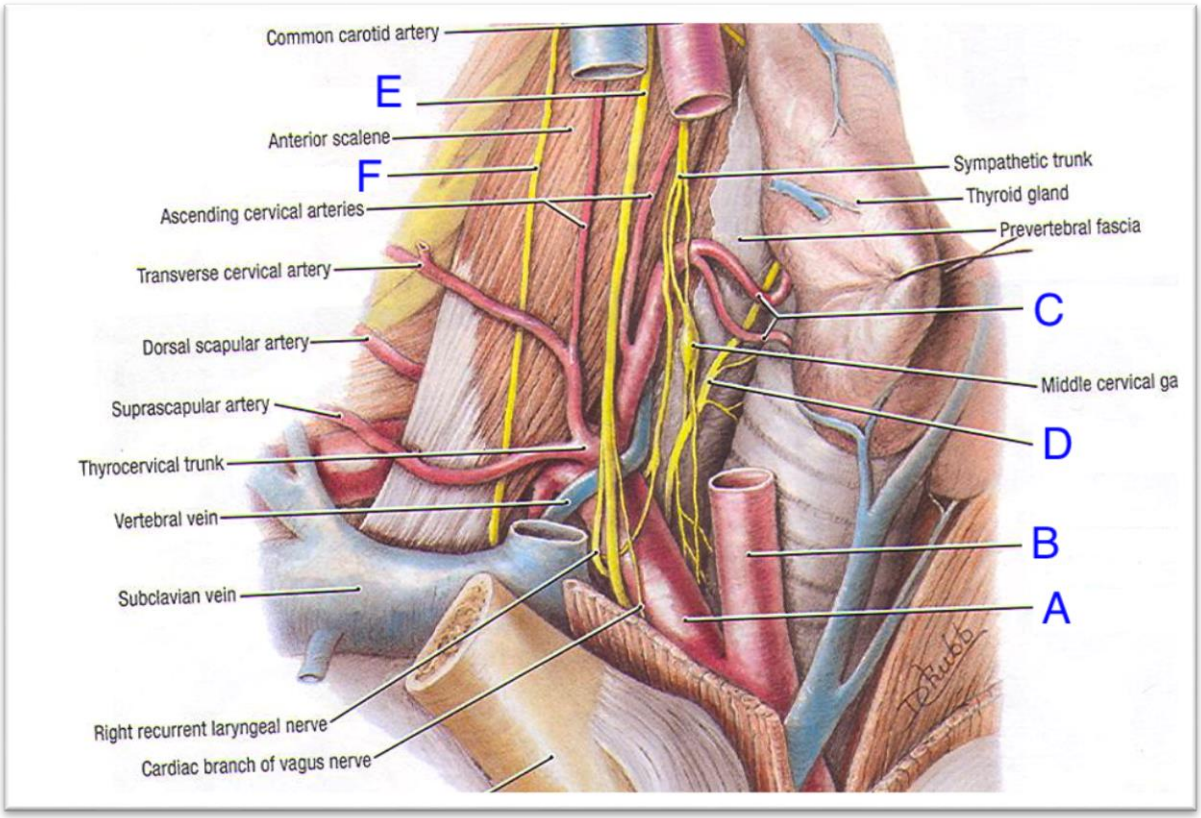

Muscles of the Root of the Neck

Scalenus Anterior Muscle
Scalenus Medius Muscle

The Thoracic Duct

The thoracic duct begins in the abdomen at the upper end of the cisterna chyli. It enters the thorax through the aortic opening in the diaphragm and ascends upward, inclining gradually to the left. On reaching the superior mediastinum, it is found passing upward along the left margin of the esophagus. At the root of the neck, it continues to ascend along the left margin of the esophagus until it reaches the level of the transverse process of the seventh cervical vertebra. Here, it bends laterally behind

the carotid sheath. On reaching the medial border of the scalenus anterior, it turns downward and drains into the beginning of the left brachiocephalic vein. It may, however, end in the terminal part of the subclavian or internal jugular veins.

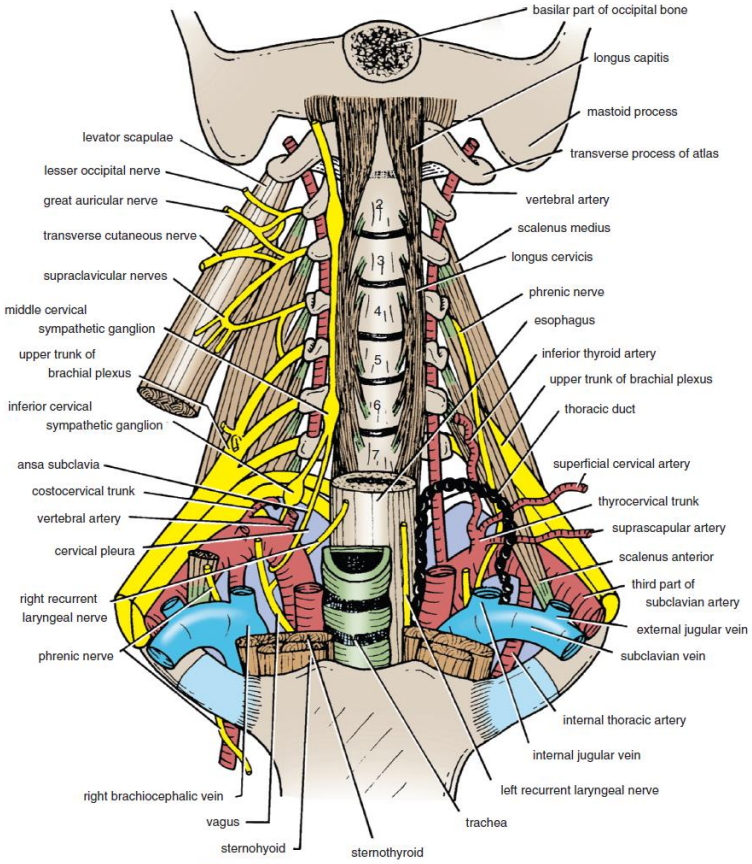

FIGURE 11.57 Prevertebral region and the root of the neck.

Main Nerves of the Neck

Cervical Plexus

Brachial Plexus

The brachial plexus is formed in the posterior triangle of the neck by the union of the anterior rami of the 5th, 6th, 7th, and 8th cervical and the first thoracic spinal nerves. This plexus is divided into **roots, trunks, divisions,** and **cords.** The roots of C5 and 6 unite to form the **upper trunk,** the root of C7 continues as the **middle trunk,** and the roots of C8 and T1 unite to form the **lower trunk.**

Each trunk then divides into **anterior** and **posterior divisions.** The anterior divisions of the upper and middle trunks unite to form the **lateral cord,** the anterior division of

the lower trunk continues as the **medial cord,** and the posterior divisions of all three trunks join to form the **posterior cord.**

The roots of the brachial plexus enter the base of the neck between the scalenus anterior and the scalenus medius muscles. The trunks and divisions cross the posterior triangle of the neck, and the cords become arranged around the axillary artery in the axilla. Here, the brachial plexus and the axillary artery and vein are enclosed in the **axillary sheath.**

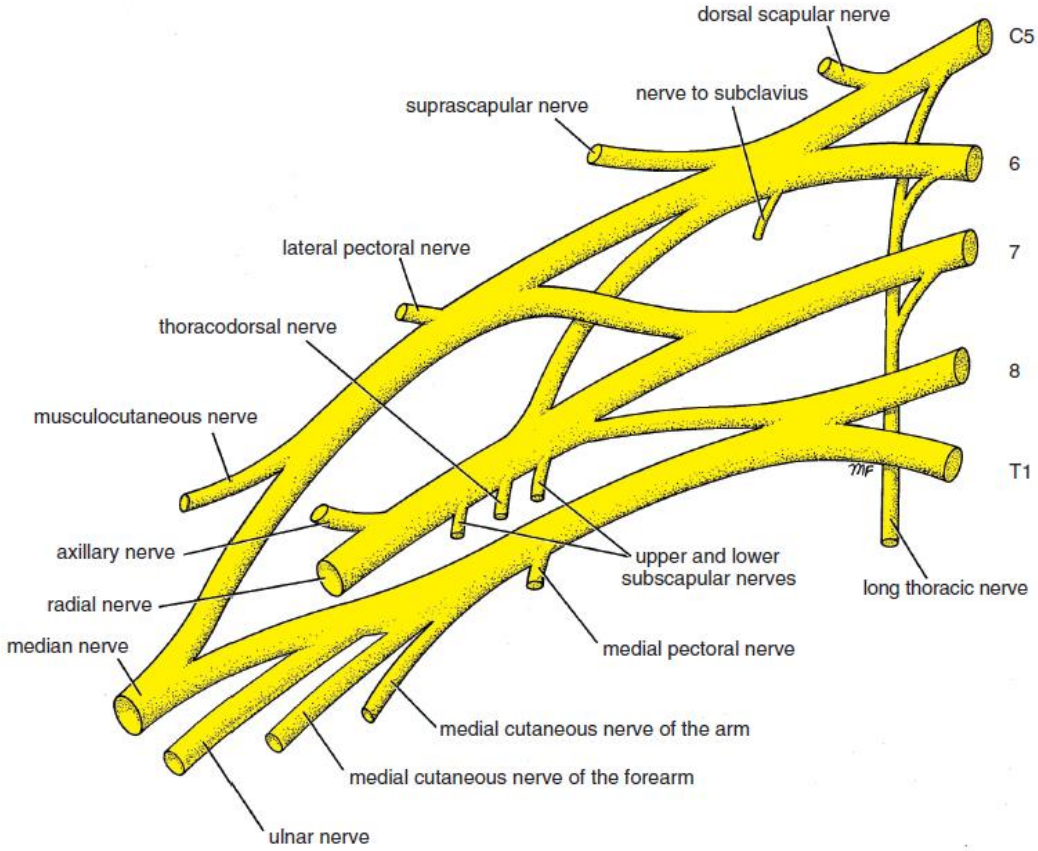

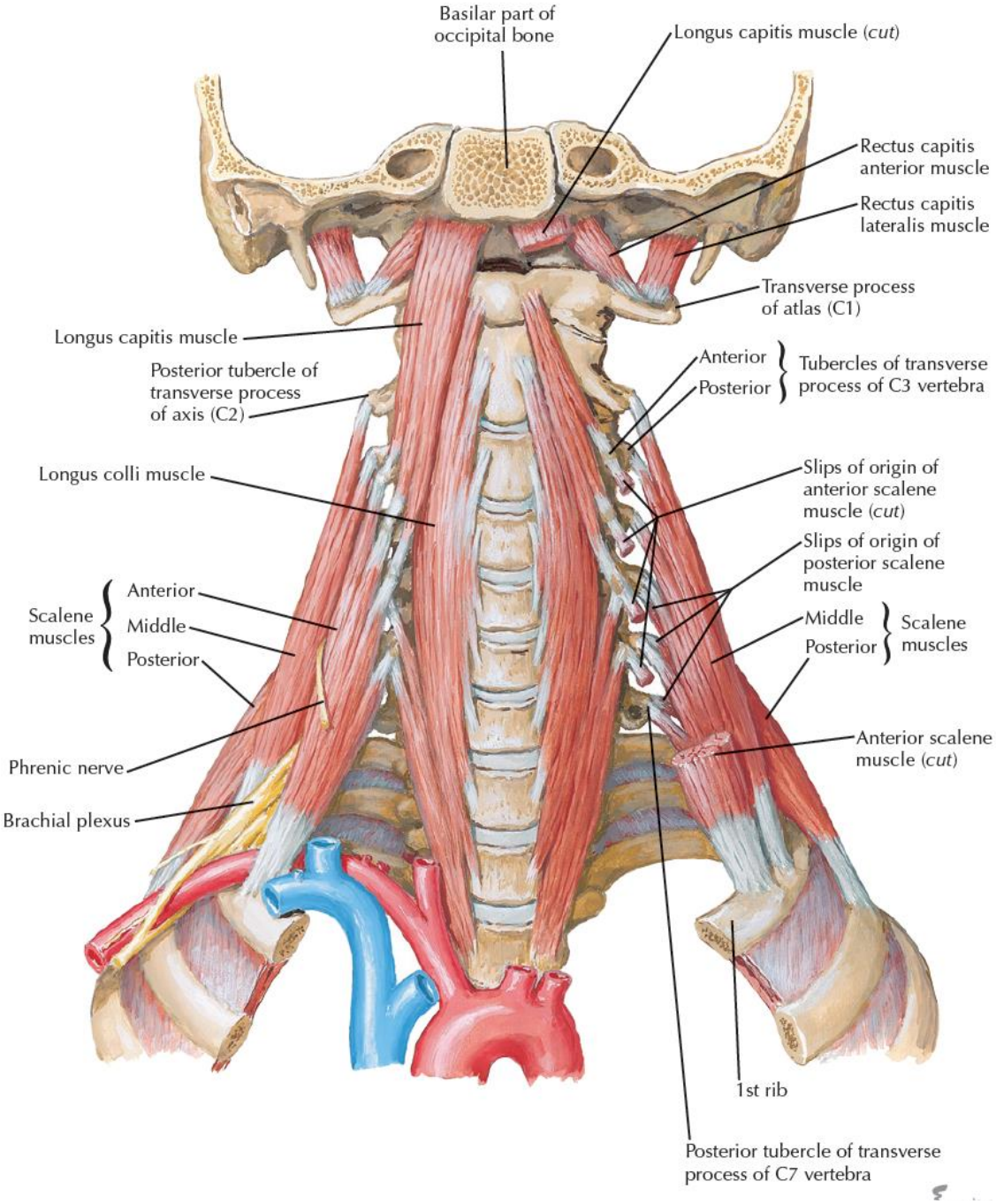
Basilar part of occipital bone
Longus capitis muscle (*cut*)
Rectus capitis anterior muscle
Rectus capitis lateralis muscle
Transverse process of atlas (C1)
Longus capitis muscle
Anterior
Posterior
Tubercles of transverse process of C3 vertebra
Posterior tubercle of transverse process of axis (C2)
Longus colli muscle
Slips of origin of anterior scalene muscle (*cut*)
Slips of origin of posterior scalene muscle
Scalene muscles
Anterior
Middle
Posterior
Middle
Posterior
Scalene muscles
Anterior scalene muscle (*cut*)
Phrenic nerve
Brachial plexus
1st rib
Posterior tubercle of transverse process of C7 vertebra

Veins of the Head and Neck

The veins of the head and neck may be divided into

1. The veins of the brain, venous sinuses, diploic veins, and emissary veins
2. The veins of the scalp, face, and neck

- **Veins of the Brain**

The veins of the brain are thin walled and have no valves. They consist of the cerebral veins, the cerebellar veins, and the veins of the brainstem, all of which drain into the neighboring venous sinuses.

- **Venous Sinuses**

The venous sinuses are situated between the periosteal and the meningeal layer of the dura mater. They have thick, fibrous walls, but they possess no valves. They receive tributaries from the brain, the skull bones, the orbit, and the internal ear. The venous sinuses include the superior and inferior sagittal sinuses, the straight sinus, the transverse sinuses, the sigmoid sinuses, the occipital sinus, the cavernous sinuses, and the superior and inferior petrosal sinuses.

- **Diploic Veins**

The diploic veins occupy channels within the bones of the vault of the skull.

- **Emissary Veins**

The emissary veins are valveless veins that pass through the skull bones. They connect the veins of the scalp to the venous sinuses (and are an important route for the spread of infection).

Veins of the scalp, face, and neck

1. Facial Vein

The facial vein is formed at the medial angle of the eye by the union of the supraorbital and supratrochlear veins. It is connected through the ophthalmic veins with the cavernous sinus. The facial vein descends down the face with the facial artery and passes around the lateral side of the mouth. It then joined by the anterior division of the retromandibular vein, and drains into the internal jugular vein.

2. Superficial Temporal Vein

The superficial temporal vein is formed on the side of the scalp. It follows the superficial temporal artery and the auriculotemporal nerve and then enters the parotid

Salivary gland, where it joins the maxillary vein to form the retromandibular vein.

3. Maxillary Vein

The maxillary vein is formed in the infratemporal fossa from the pterygoid venous plexus. The maxillary vein joins the superficial temporal vein to form the retromandibular vein.

4. Retromandibular Vein

The retromandibular vein is formed by the union of the superficial temporal and the maxillary veins. On leaving the parotid salivary gland, it divides into an anterior branch, which joins the facial vein, and a posterior branch, which joins the posterior auricular vein to form the external jugular vein.

5. External Jugular Vein

The external jugular vein is formed behind the angle of the jaw by the union of the posterior auricular vein with the posterior division of the retromandibular vein.
It descends across the sternocleidomastoid muscle and beneath the platysma muscle, and it drains into the subclavian vein behind the middle of the clavicle.

6. Anterior Jugular Vein

The anterior jugular vein descends in the front of the neck close to the midline. Just above the sternum, it is joined to the opposite vein by the jugular arch. The anterior jugular vein joins the external jugular vein deep to the sternocleidomastoid muscle.

7. Internal Jugular Vein

The internal jugular vein is a large vein that receives blood from the brain, face, and neck . It starts as a continuation of the sigmoid sinus and leaves the skull through the jugular foramen. It then descends through the neck in the carotid sheath lateral to the vagus nerve and the internal and common carotid arteries. It ends by joining the subclavian vein behind the medial end of the clavicle to form the brachiocephalic vein. Throughout its course, it is closely related to the deep cervical lymph nodes..

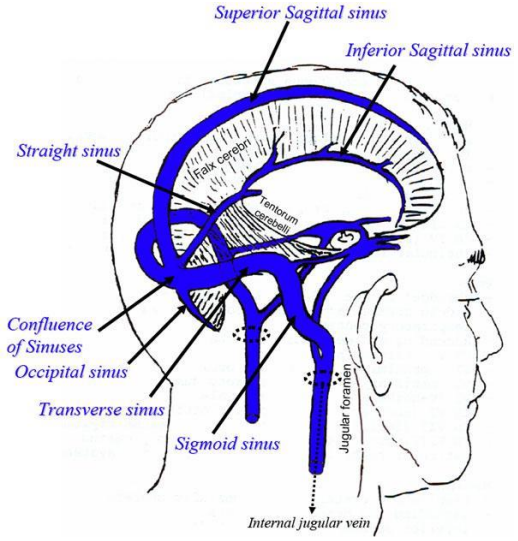

Tributaries of the Internal Jugular Vein

1) Inferior petrosal sinus
2) Facial vein
3) Pharyngeal veins
4) Lingual vein
5) Superior thyroid vein
6) Middle thyroid vein

Subclavian Vein

The subclavian vein is a continuation of the axillary vein at the outer border of the 1st rib. It joins the internal jugular vein to form the brachiocephalic vein, and it receives the external jugular vein. In addition, it often receives the thoracic duct on the left side and the right lymphatic duct on the right.

Relations

Anteriorly: The clavicle
Posteriorly: The scalenus anterior muscle and the phrenic nerve
Inferiorly: The upper surface of the 1st rib

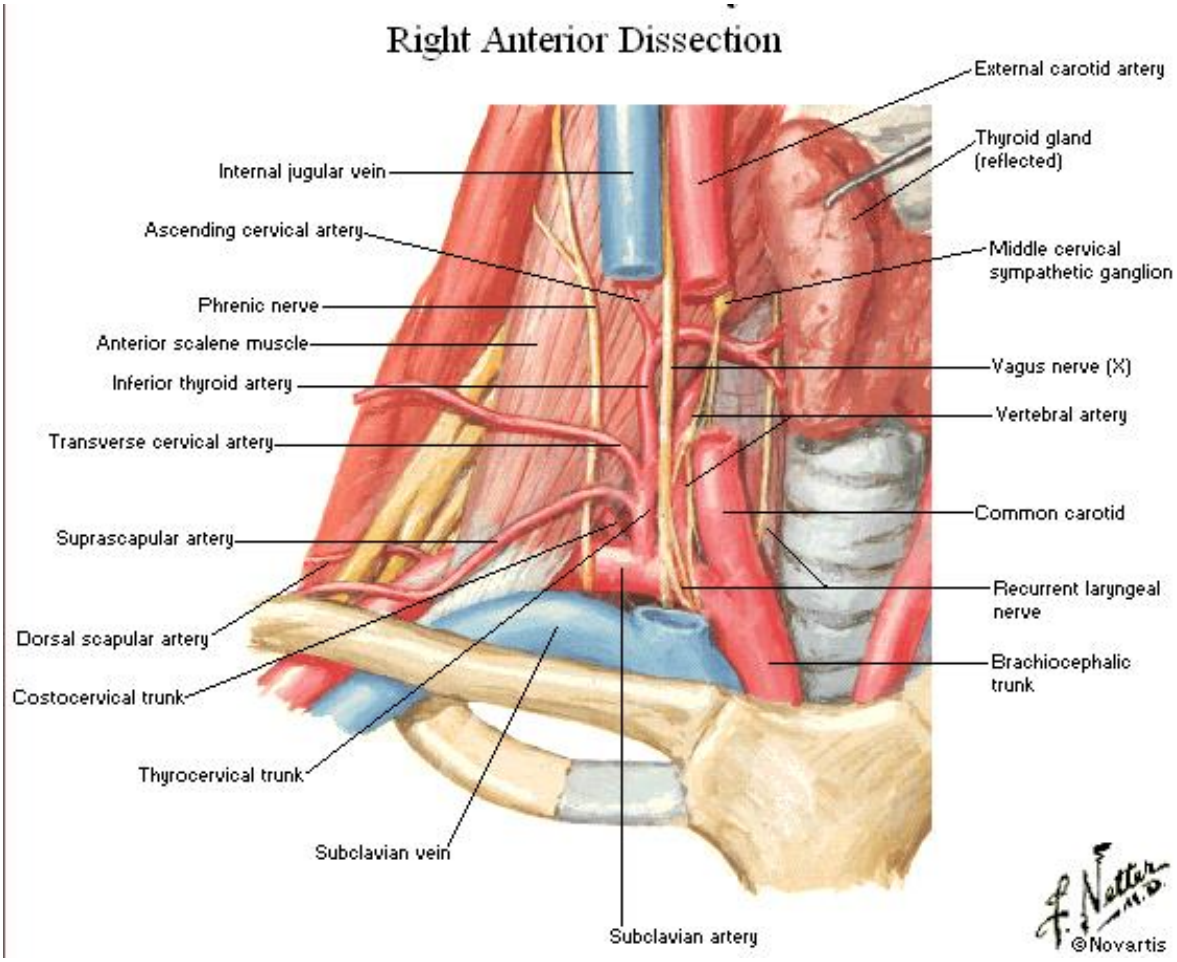

Lymph Drainage of the Head and Neck

The lymph nodes of the head and neck are arranged as a regional collar that extends from below the chin to the back of the head and as a deep vertical terminal group that is embedded in the carotid sheath in the neck.

Regional Nodes

The regional nodes are arranged as follows:

■■ **Occipital nodes:** These are situated over the occipital bone on the back of the skull. They receive lymph from the back of the scalp.

■■ **Retroauricular (mastoid) nodes:** These lie behind the ear over the mastoid process. They receive lymph from the scalp above the ear, the auricle, and the external auditory meatus.

■■ **Parotid nodes:** These are situated on or within the parotid salivary gland. They receive lymph from the scalp above the parotid gland, the eyelids, the parotid gland, the auricle, and the external auditory meatus.

■■ **Buccal (facial) nodes:** One or two nodes lie in the cheek over the buccinator muscle. They drain lymph that ultimately passes into the submandibular nodes.

■■ **Submandibular nodes:** These lie superficial to the submandibular salivary gland just below the lower margin of the jaw. They receive lymph from the front of the scalp; the nose; the cheek; the upper lip and the lower lip (except the central part); the frontal, maxillary, and ethmoid sinuses; the upper and lower teeth (except the lower incisors); the anterior two thirds of the tongue (except the tip); the floor of the mouth and vestibule; and the gums.

Submental nodes: These lie in the submental triangle just below the chin. They drain lymph from the tip of the tongue, the floor of the anterior part of the mouth, the incisor teeth, the center part of the lower lip, and the skin over the chin.

■■ **Anterior cervical nodes:** These lie along the course of the anterior jugular veins in the front of the neck. They receive lymph from the skin and superficial tissues of the front of the neck.

■■ **Superficial cervical nodes:** These lie along the course of the external jugular vein on the side of the neck. They drain lymph from the skin over the angle of the jaw, the skin over the lower part of the parotid gland, and the lobe of the ear.

■■ **Retropharyngeal nodes:** These lie behind the pharynx and in front of the vertebral column. They receive lymph from the nasal pharynx, the auditory tube, and the vertebral column.

■■ **Laryngeal nodes:** These lie in front of the larynx. They receive lymph from the larynx.
■■ **Tracheal (paratracheal) nodes:** These lie alongside the trachea. They receive lymph from neighboring structures, including the thyroid gland.

Deep Cervical Nodes

The deep cervical nodes form a vertical chain along the course of the internal jugular vein within the carotid sheath. They receive lymph from all the groups of regional nodes. The **jugulodigastric node,** which is located below and behind the angle of the jaw, is mainly concerned with drainage of the tonsil and the tongue. The **juguloomohyoid node,** which is situated close to the omohyoid muscle, is mainly associated with drainage of the tongue. The efferent lymph vessels from the deep cervical lymph nodes join to form the jugular trunk, which drains into the thoracic duct or the right lymphatic duct.

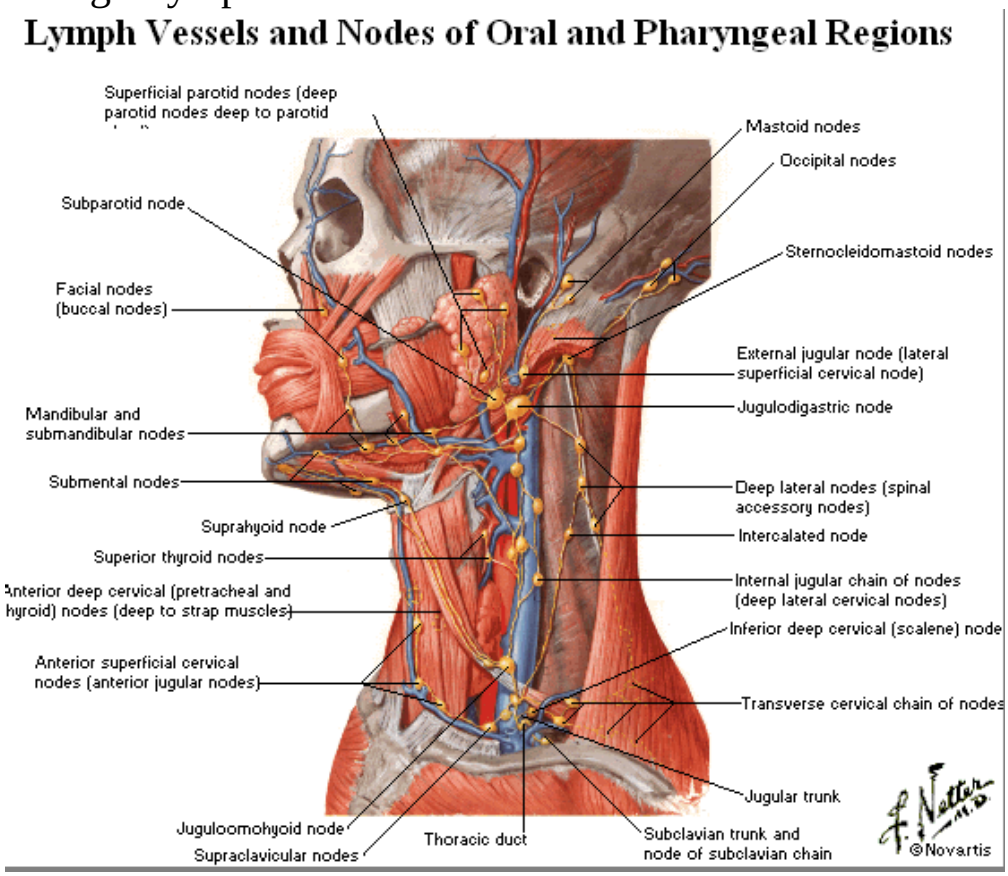

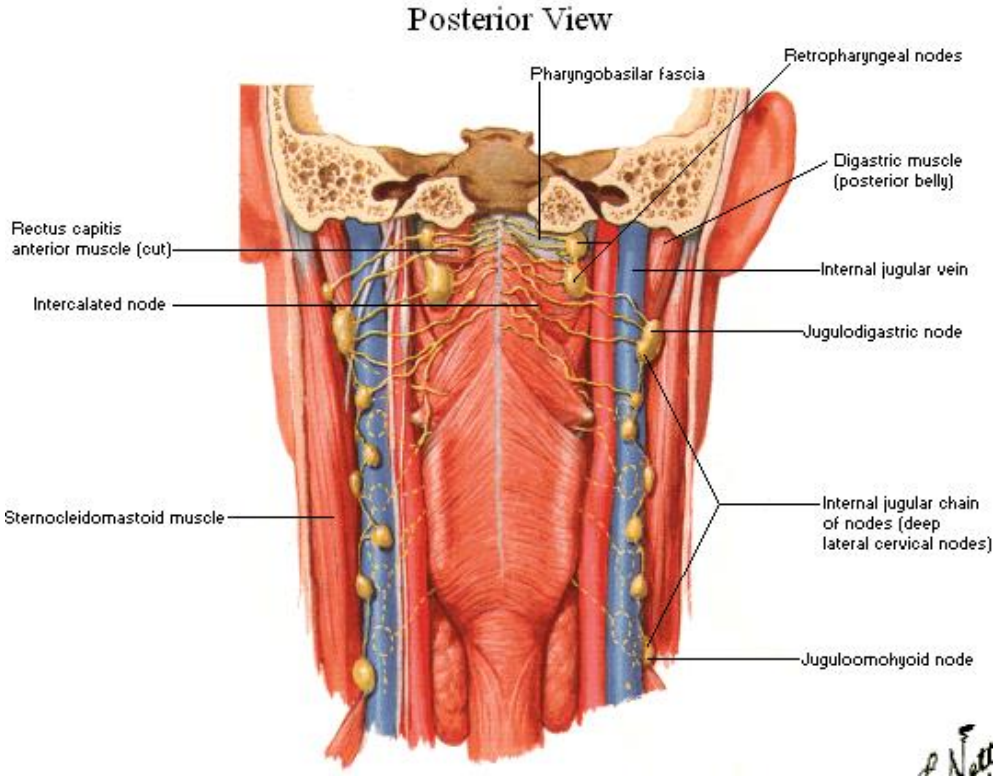
Posterior View
Pharyngobasilar fascia
Retropharyngeal nodes
Digastric muscle
(posterior belly)
Rectus capitis
anterior muscle (cut)
Internal jugular vein
Intercalated node
Jugulodigastric node
Sternocleidomastoid muscle
Internal jugular chain
of nodes (deep
lateral cervical nodes)
Juguloomohyoid node